




Since January 2020 Elsevier has created a COVID-19 resource centre with free information in English and Mandarin on the novel coronavirus COVID-19. The COVID-19 resource centre is hosted on Elsevier Connect, the company's public news and information website.

Elsevier hereby grants permission to make all its COVID-19-related research that is available on the COVID-19 resource centre - including this research content - immediately available in PubMed Central and other publicly funded repositories, such as the WHO COVID database with rights for unrestricted research re-use and analyses in any form or by any means with acknowledgement of the original source. These permissions are granted for free by Elsevier for as long as the COVID-19 resource centre remains active.



Treatment and outcomes of pediatric patients with cancer and COVID-19 at MAHAK pediatric cancer treatment and research center, Tehran, Iran

Azim Mehrvar^a, Ibrahim Qaddoumi^b, Maryam Tashvighi^a, Ali Naderi^a, Hadi Mousakhani^a, Ramin Alasvand^a, Babak Shekarchi^a, Negar Afsar^a, Mahyar Nourian^a, Narjes Mehrvar^{a,*}

^aMAHAK Hematology Oncology Research Center (MAHAK-HORC), MAHAK Hospital, Shahid Beheshti University of Medical Sciences, Tehran, Iran

^bSt. Jude Children's Research Hospital, Memphis, Tennessee

ARTICLE INFO

Article history:

Received 21 April 2021

Revised 11 August 2021

Accepted 1 September 2021

KEYWORDS:

COVID-19
cancer
pediatrics
coronavirus

ABSTRACT

The COVID-19 pandemic has been particularly devastating for Iran. Children with cancer are generally immunosuppressed and especially vulnerable to SARS-CoV-2 infections. We report the treatment and outcomes of pediatric oncology patients with COVID-19 at the MAHAK Pediatric Cancer Treatment and Research Center (MPCTRC) in Tehran. We enrolled pediatric oncology patients who experienced SARS-CoV-2 infections from March 18, 2020, to January 28, 2021. The COVID-19 diagnostic criteria at MPCTRC were based on imaging and clinical presentation because of specific challenges diagnosing SARS-CoV-2 infections with molecular testing, which was locally developed and conducted at centers other than MPCTRC. We enrolled nine outpatients and eight inpatients (mean age = 9 years), seven of whom had a diagnosis of leukemias, and five who had brain tumors. COVID-19 symptoms were mild in fourteen patients, and three patients were asymptomatic. Of twelve patients who received molecular testing for SARS-CoV-2 infection, eight were negative and four were positive. Of nine patients tested for IgG and IgM antibodies, one was positive. Three patients died of COVID-19, all of whom were hospitalized. Mild COVID-19 symptoms did not appear to affect the outcomes of the pediatric patients with cancer who received treatment at MPCTRC during the study period.

© 2021 The Author(s). Published by Elsevier Inc.

This is an open access article under the CC BY license (<http://creativecommons.org/licenses/by/4.0/>)

Introduction

Sudden acute respiratory syndrome coronavirus 2 (SARS-CoV-2), which causes coronavirus disease 2019 (COVID-19), introduced an important public health threat in the world beginning in 2019 [1]. Originating from Wuhan, China [2], SARS-CoV-2 can easily transmit from person to person [3]. Initial reports suggested that COVID-19 is uncommon in children [1,4–6]. In April 2020, however, She *et al.* reported a precipitous increase in the number of children infected with SARS-CoV-2 [7]. The virus primarily targets the respiratory system, which can lead to pneumonia [8]. The clinical features of children with COVID-19 are similar to those of adults but are generally milder [9].

From March 7 to March 30, 2020, SARS-CoV-2 infections were diagnosed in thirty-five children at Tehran University of Medical Sciences. Of these children, 22 were boys, and their median age

was 7.5 years (range, 4 months to 15 years old). Of these 35 pediatric COVID-19 cases in Tehran, 29 resulted from family exposure to SARS-CoV-2. Nearly 86% of patients received oseltamivir, and 63% were administered hydroxychloroquine. In addition, many patients received azithromycin, cefotaxime, and/or ceftriaxone [10].

Patients with cancer have a higher risk of morbidity and mortality than does the rest of the population because of their compromised immune status secondary to cancer or its treatment [11–14]. However, no reports of Iranian pediatric patients with cancer who experienced SARS-CoV-2 infections have been published. Therefore, we evaluated the characteristics and follow-up care of pediatric oncology patients with COVID-19 who received treatment at the MAHAK Pediatric Cancer Treatment and Research Center (MPCTRC). MPCTRC is a non-governmental charity-based organization that provides multidisciplinary care for pediatric patients with cancer. Despite administrative safety and protective controls at the time of the COVID-19 pandemic, some patients receiving care at MPCTRC experienced symptoms that met our diagnostic criteria for COVID-19. We describe the COVID-19 clinical presentation, treatment, and outcomes of these children.

* Corresponding author. MAHAK Hematology Oncology Research Center (MAHAK-HORC), MAHAK Hospital, Shahid Beheshti University of Medical Sciences, Tehran, Iran, Tel.: +989125161371, Fax: +982123501344

E-mail address: narjes.mehrvar@gmail.com (N. Mehrvar).

Table 1
Clinical presentation of COVID-19.

Infection Severity	Carlotti et al [15]	Dong et al [16]
Asymptomatic	Absence of clinical signs and symptoms of the disease and normal chest X-ray scan associated with a positive test for SARS-CoV-2	Without any clinical symptoms and signs, and the chest imaging results normal, whereas the 2019-nCoV nucleic acid test result is positive
Mild	Upper airway symptoms such as fever, fatigue, myalgia, cough, sore throat, runny nose and sneezing. Pulmonary clinical exam is normal. Some cases may not have fever and others may experience gastrointestinal symptoms such as nausea, vomiting, abdominal pain and diarrhea	Symptoms of acute upper respiratory tract infection, including fever, fatigue, myalgia, cough, sore throat, runny nose, and sneezing. Physical examination shows congestion of the pharynx and no auscultatory abnormalities. Some cases may have no fever or have only digestive symptoms, such as nausea, vomiting, abdominal pain, and diarrhea
Moderate	Clinical signs of pneumonia. Persistent fever, initially dry cough, which becomes productive, may have wheezing or crackles on pulmonary auscultation but show no respiratory distress. Some individuals may not have symptoms or clinical signs, but chest scan reveals typical pulmonary lesions	With pneumonia, frequent fever, and cough (mostly dry cough, followed by productive cough); some may have wheezing, but no obvious hypoxemia such as shortness of breath, and lungs can hear sputum or dry and/or wet snoring. Some cases may have no clinical signs and symptoms, but chest computed tomography shows lung lesions, which are subclinical
Severe	Initial respiratory symptoms may be associated with gastrointestinal symptoms such as diarrhea. The clinical deterioration usually occurs in a week with the development of dyspnea and hypoxemia (blood oxygen saturation [SaO ₂] <94%	Early respiratory symptoms, such as fever and cough, may be accompanied by gastrointestinal symptoms, such as diarrhea. The disease usually progresses at ~1 week, and dyspnea occurs with central cyanosis. Oxygen saturation is <92% with other hypoxia manifestations
Critical	Patients can quickly deteriorate to acute respiratory distress syndrome or respiratory failure and may present shock, encephalopathy, myocardial injury or heart failure, coagulopathy, acute kidney injury, and multiple organ dysfunction	Children can quickly progress to acute respiratory distress syndrome or respiratory failure and may also have shock, encephalopathy, myocardial injury or heart failure, coagulation dysfunction, and acute kidney injury. Organ dysfunction can be life-threatening

Patients and methods

Study design and patients

We performed a cross-sectional, retrospective study of children with cancer who received treatment at MPCTRC from March 18, 2020, to January 28, 2021, and met our diagnostic criteria for SARS-CoV-2 infection. Two children with COVID-19 who were referred to other Iranian centers for treatment were excluded from the study. These two patients had newly diagnosed cancer, and their parents elected for treatment at pediatric cancer units closer to their homes. The data collected included patient sex, age at the time COVID-19 diagnosis, and cancer type. We also evaluated laboratory test findings, imaging studies, types of cancer-directed therapy, and patient status at their last follow-up visits. The study was approved by the MAHAK ethical committee (IR. MAHAK.RESEARCH.1399.230)

Clinical presentations

We used the COVID-19 clinical presentations described by Carlotti *et al.* and Dong *et al.*[15,16] to divide the clinical symptoms of our patients into five categories: asymptomatic, mild, moderate, severe, and critical (Table 1). All patients with cough, fever, and/or respiratory symptoms (with or without digestive symptoms) were screened for SARS-CoV-2 infection.

Laboratory tests

At the time of admission, patients had laboratory testing performed for white blood cell count, absolute neutrophil count, absolute lymphocyte count, and C-reactive protein level [17].

Imaging evaluation

Chest computed tomography (CT) scans were performed for all patients with suspected COVID-19 at the time of their first reported symptoms to evaluate the severity of SARS-CoV-2 infections because children with severe infections exhibit bilateral multiple lobar lesions [17].

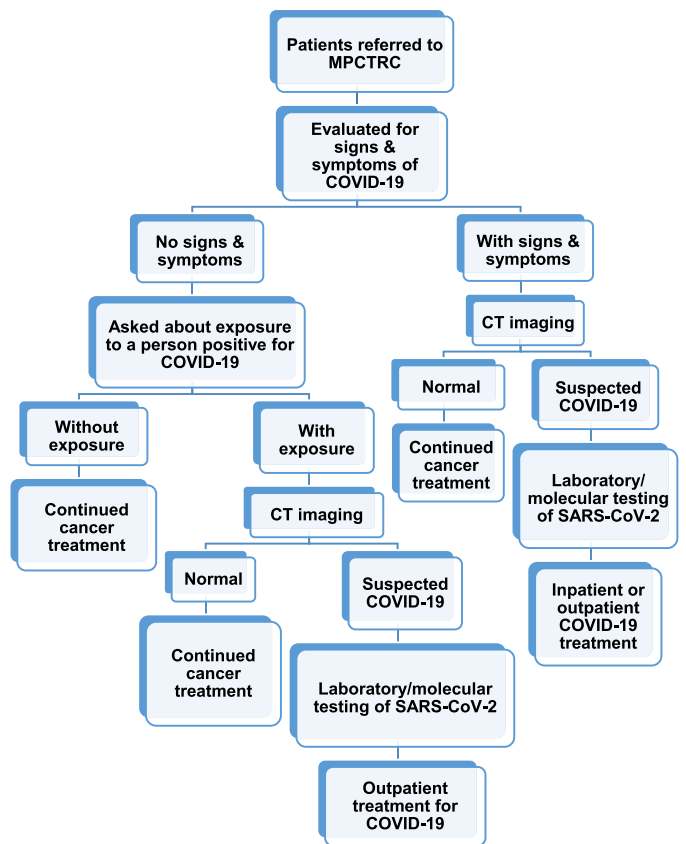


Fig. 1. Flow chart of the diagnostic and treatment workflow for pediatric patients with cancer and COVID-19 treated at MPCTRC in Tehran, Iran. Schematic evaluation of patients with COVID-19.

Detection of SARS-CoV-2 infections

Real-time reverse transcriptase polymerase chain reaction (RT-PCR) can detect the presence of SARS-CoV-2 nucleic acids in infected tissues [18]. Therefore, nasopharynx or nasal swabs were

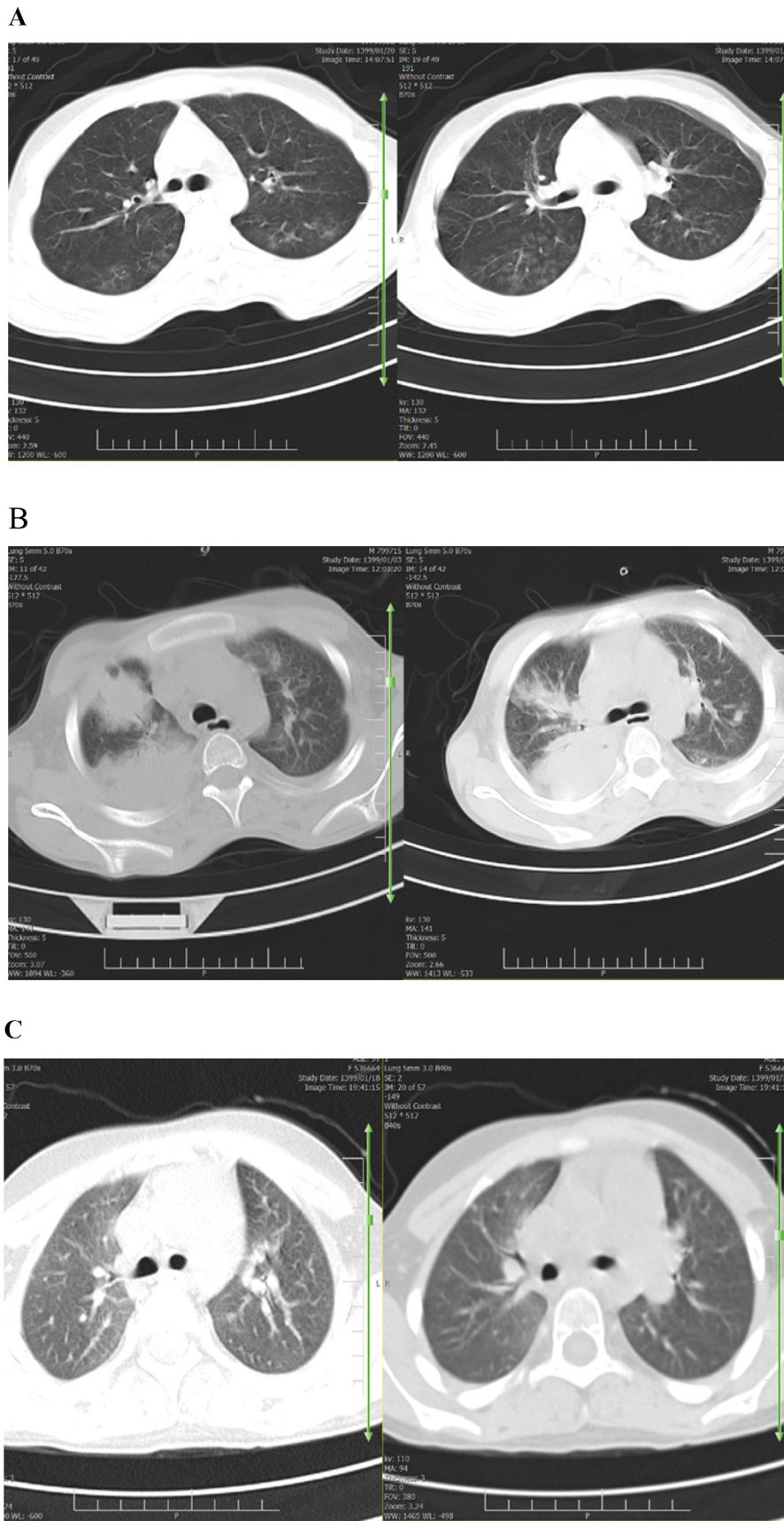


Fig. 2. Computed tomography images without contrast of lungs from three patients. Panels A and B, from cases 2, and 3, respectively, from the inpatient cohort. Panel C from case 10 of the outpatient cohort.

Table 2
Clinical characteristics of pediatric patients with cancer and COVID-19 treated at MPCTRC in Tehran, Iran.

Characteristics		Inpatient cohort[n=8]	Outpatient cohort[n=9]	Total patients[n=17]
Sex	Male	5	5	10
	Female	3	4	7
Age at the time of symptoms	Mean ± SE (years)	12.6 ± 2.5	6.1 ± 1.1	9.17 ± 1.5
	Range (years)	3–25	3–13	3–25
	No. patients <5 years	2	3	5
Cancer diagnoses	Leukemia	4	3	7
	Brain tumor	0	5	5
	Lymphoma	3	0	3
	Sarcoma	1	1	2
Number treated for recurrence		5	4	9

SE = standard error.

collected from the patients at the time of reporting their first symptoms. Because of global shortages of RT-PCR test reagents at the beginning of the COVID-19 pandemic, RT-PCR was performed only in patients with severe or critical COVID-19 symptoms [15,19].

Diagnosis of COVID-19 at MPCTRC

The COVID-19 diagnostic criteria at MPCTRC were based on clinical symptoms, known exposure to SARS-CoV-2, and CT imaging findings. RT-PCR was not performed for all suspected cases because it was developed locally at other hospitals and its quality assurance could not be confirmed or validated at the time of diagnosis. CT imaging was performed at the time of diagnosis and at 14 days after treatment or supportive care. Fig. 1 depicts a schematic diagram of the diagnostic and treatment workflow for the patients who were referred to MPCTRC during the study period.

Treatment of COVID-19 at MPCTRC

Treatment of SARS-CoV-2 infections at MPCTRC was based on CT findings and clinical symptoms rather than nasal swab/RT-PCR results. The inpatient cohort (n=8, all symptomatic) consisted of patients who were hospitalized and received oseltamivir, an antiviral medication used to treat influenza, and hydroxychloroquine, in consultation with a pediatric infectious diseases specialist [20], in addition to azithromycin [15]. The outpatient cohort (n=9, three asymptomatic and six symptomatic) consisted of patients who were observed at home and received supportive care (ie, intravenous fluids) with azithromycin (10 mg/kg on the first day, then 5 mg/kg per day for 4 days) [15].

Oseltamivir was administered for 5 days according to body weight for patients older than 12 months: 15–23 kg received 45 mg twice per day; 24–40 kg received 60 mg twice per day; and ≥40 kg received 75 mg twice per day [20]. Hydroxychloroquine (5 mg/kg per day) was administered for 10 days, and 10 mg/kg azithromycin was administered on the first day of treatment followed by 5 mg/kg per day for 4 days [15]. Hospitalization and treatment were offered for the six symptomatic patients in the outpatient cohort, but the parents refused. Therefore, these six patients were treated at home with intravenous fluids and oral azithromycin. Cancer-directed therapies (radiation and chemotherapy) were suspended for all patients until recovery from COVID-19 symptoms, except for two patients who had finalized their treatment and were receiving follow-up examinations.

Statistical analysis

Statistical analyses were performed with SPSS software, version 23. Parametric and nonparametric analyses were performed, as appropriate.

Results

Patients

From March 18, 2020, to January 28, 2021, 637 pediatric patients were admitted to or visited MPCTRC for cancer diagnoses and treatment. Of these, 356 had newly diagnosed neoplasms. COVID-19 was suspected in two of these new cases at the time of admission. However, the parents of these children preferred treatment at other centers closer to their homes and were therefore excluded from our analysis.

A total of 17 patients who received treatment at MPCTRC were eligible for our study. All 17 patients had previous exposure to a person with COVID-19. Fourteen patients exhibited clinical symptoms consistent with COVID-19, and three were asymptomatic. All 17 cases had CT findings consistent with COVID-19. The most common cancer diagnoses in our cohort included leukemia (n=7), brain tumors (n=5) and lymphoma (n=3). The patients with leukemias had acute lymphoblastic leukemia (ALL, n=4) and acute myeloid leukemia (AML, n=3). The patients with brain tumors had pilocytic astrocytoma (n=2), ependymoma (n=1), optic pathway glioma (n=1), and medulloblastoma (n=1). The patients with lymphoma diagnoses comprised Burkitt lymphoma (n=1), Hodgkin lymphoma (n=1), and non-Hodgkin lymphoma (n=1). Finally, the two remaining cases had rhabdomyosarcoma (n=1) and osteosarcoma (n=1). The clinical characteristics of the two patient cohorts (ie, inpatient and outpatient) are summarized in Table 2.

Clinical presentations

All COVID-19 symptoms were mild in the 14 patients who exhibited symptoms. Of these patients, 71.4%, 42.9%, and 28.6% had fever, upper airway symptoms, and cough, respectively. All eight patients in the inpatient cohort had mild symptoms (fever, 62.5%; upper airway symptoms, 50%; and cough, 37.5%). Of the six symptomatic patients in the outpatient group, all had mild clinical symptoms and were referred with fever (83.3%), and only two cases exhibited upper airway symptoms, with one experiencing cough.

Laboratory tests

Laboratory test findings in the all patients and the inpatient and outpatient cohorts are provided in Table 3. The laboratory test findings were unremarkable for the total patient population and each cohort.

Imaging evaluations

Chest CT imaging findings are summarized in Table 4. These findings were based on chest axial spiral CT scans without con-

Table 3

Laboratory test findings of pediatric patients with cancer and COVID-19 treated at MPCTRC in Tehran, Iran.

Laboratory test	Inpatient cohort		Outpatient cohort		All patients	
	Mean ± SE	Range	Mean ± SE	Range	Mean ± SE	Range
WBC (cells/L)	6,217 ± 3,501	320–15,970	6,481 ± 2,976	200–19,300	6,375 ± 2,142	200–19,300
ANC (cells/L)	10,331 ± 5,313	263–18,307	5,565 ± 2,430	1,777–12,552	7,607 ± 2,578	263–18,307
ALC (cells/L)	968 ± 493	34–1,709	2,232 ± 720	567–4080	1,690.6 ± 498	34–4,080
Platelets (cells/L)	46,500 ± 19,538	6,000–99,0000	188,333 ± 86,963	12,000–592,000	131,600 ± 55,751	6,000–592,000
Hgb (g/dL)	10.1 ± 1.2	6.6–12.1	9.7 ± 1.2	7–14	9.8 ± 0.8	6.6–14
CRP (mg/L)	67.4 ± 42.4	6–192	31.5 ± 10.2	6–48	49.5 ± 21.3	6–192
LDH (IU/L)	474 ± 161	241–784	542 ± 163	241–784	508 ± 103	241–868

ALC=absolute lymphocyte count; ANC=absolute neutrophil count; CRP=C-reactive protein; Hgb=hemoglobin; LDH=lactate dehydrogenase; SE=standard error; WBC=white blood cell count.

Table 4

Chest computed tomography imaging findings in pediatric patients with cancer and COVID-19 treated at MPCTRC in Tehran, Iran.

Case Number	Cohort	Age (years)	Computed tomography (CT) imaging findings
1	Inpatient	13	Significant ground-glass opacity with peripheral location, pleural effusion
2	Inpatient	16	Moderate ground-glass opacity with peripheral location
3	Inpatient	13	Significant ground-glass opacity with peripheral location, pericardial effusion, mild pleural effusion
4	Inpatient	25	Peripheral ground-glass opacities
5	Outpatient	3	Poor quality
6	Outpatient	7	Ground-glass opacity
7	Outpatient	5	Moderate ground-glass opacity with peripheral location
8	Outpatient	3	Poor quality
9	Outpatient	3	Bilateral peripheral opacities
10	Outpatient	9	Nodular opacities in the parenchyma of both lungs
11	Outpatient	5	Low-grade COVID-19 pneumonia
12	Inpatient	10	Massive extensive bilateral multi-lobar ground glass opacity and consolidations with air bronchograms
13	Outpatient	13	Not applicable
14	Inpatient	3	Both lung, but predominantly right lung with multi-lobar ground glass opacity and consolidation
15	Outpatient	7	In both lung lower lobes consolidation and air bronchograms seen
16	Inpatient	4	Bilateral multi-lobar consolidation with ground glass opacities with air bronchograms and small right side pleural effusion
17	Inpatient	17	Bilateral pulmonary subpleural patchy infiltration

Table 5

Summary of cancer diagnoses, treatment, and outcomes of pediatric patients with cancer and COVID-19 treated at MPCTRC in Tehran, Iran.

Case no.	Sex	Cancer type	Cancer therapy phase at the time of COVID-19	RT	BMT	Tumor recurrence	COVID-19 symptoms	RT-PCR results	IgG/IgM levels	COVID-19 outcomes
1	F	NHL	Course AA with BFM-NHL-90 protocol	No	No	0	Fever, UAS	Neg	ND	Recovered
2	M	BL	Chemotherapy with RICE for relapse	No	No	1	Fever, cough	Neg	ND	Death
3	M	OS	Chemotherapy after surgery	No	No	0	UAS	ND	ND	Death
4	M	AML	Relapse after BMT	No	Yes	1	Cough	Neg	Neg	Recovered
5	F	OPG	Maintenance with vincristine and carboplatin	No	No	0	Fever	ND	ND	Recovered
6	F	PA	Metronomic therapy with vinblastine	No	No	1	Asymptomatic	ND	ND	Recovered
7	M	ALL	Intensification 2 with isolated CNS relapse protocol	No	No	2	Fever, UAS	Neg	ND	Recovered
8	F	ALL	Phase II induction ALL-BFM 2009	No	No	0	Fever, cough	Neg	Neg	Recovered
9	M	EP	Course A in postoperative chemotherapy without irradiation	Yes	No	1	Asymptomatic	ND	Neg	Recovered
10	F	MB	Cycle 5 high-risk medulloblastoma	Yes	No	1	Fever	ND	Neg	Recovered
11	M	RMS	Week 24, regimen 47 RMS	Yes	No	0	Asymptomatic	Neg	Neg	Recovered
12	M	ALL	Subsequent maintenance for ALL relapse	Yes	No	1	UAS	Pos	ND	Death
13	M	ALL	Maintenance ALL-BFM 2009	No	No	0	Fever	Neg	Pos	Recovered
14	M	AML	Maintenance IBFM-2012	No	No	0	Fever, UAS	Neg	Neg	Recovered
15	M	PA	Follow-up after finalizing treatment	No	No	0	UAS	Pos	Neg	Recovered
16	F	AML	Reinduction with HAM	No	No	1	Fever	Pos	Neg	Recovered
17	F	HL	Follow-up after finalizing treatment	No	Yes	1	Fever, cough	Pos	ND	Recovered

ALL=acute lymphoblastic leukemia; AML=acute myeloid leukemia; BL=Burkitt lymphoma; BMT=bone marrow transplant; CNS=central nervous system; EP=ependymoma; F=female; M=male; MB=medulloblastoma; ND=not determined; Neg=negative; NHL=non-Hodgkin lymphoma; OPG=optic pathway glioma; OS=osteosarcoma; PA=pilocytic astrocytoma; RB=retinoblastoma; RMS=rhabdomyosarcoma; RT=radiation therapy; UAS=upper airway symptoms.

Table 6
Studies reporting COVID-19 in pediatric patients with a diagnosis of cancer.

Hrusak et al [26]	Flash survey on COVID 19 incidence and severity among children on anticancer treatment Reports from 25 countries where up to 10,000 patients at risk are followed	<ul style="list-style-type: none"> • 9/>200 children tested were found to have + COVID-19 test • 8/9 had mild or asymptomatic disease • Diagnoses: osteosarcoma after mediastinal RT (1); hepatoblastoma after adjuvant chemotherapy (1) or after cisplatin (1); rhabdoid tumor after chemotherapy (1); Ewing's sarcoma after chemotherapy (1); Wilms tumor after chemotherapy (1); ALL (2); solid tumor (1) 	<p>Author conclusions:</p> <ul style="list-style-type: none"> • Should not delay oncologic treatment <p>Limitations:</p> <ul style="list-style-type: none"> • Many centers tested only symptomatic patients hence true rate of infection not known • 4/9 cases same as reported by Balduzzi et al
Boulad et al [27]	COVID-19 in children with cancer in New York City Period of study: March 10 -April 12, 2020	<ul style="list-style-type: none"> • Pediatric patients with a diagnosis of cancer testing positive for COVID: • All: 20/178 (11.2%) • Patients exposed to COVID 19 or symptom positive: 17/58 (29.3%) • No exposure to COVID or symptom negative: 3/120 (2.5%) • [Yes/No exposure to COVID or symptoms: 29.3% (95%CI 18.1-42.7%) v 2.5% (95%CI 0.5-7.1%), $P < .001$] • Male/Female + test ($P = .02$) • Male, 17/107 = 15.9% • Female, 3/71 = 4.2% • Treatment • 1/20 admitted for non-critical care • 3/20 admitted for fever/neutropenia • Caregiver testing • 14.7% + rate of SARS-CoV-2 in asymptomatic caregivers 	<p>Author conclusions:</p> <ul style="list-style-type: none"> • Overall morbidity of COVID 19 in pediatric patients with cancer is low with only 5% requiring hospitalization • Rate of SARS-CoV-2 infection amongst asymptomatic patients is low • As seen in adults there is a male bias <p>Limitations:</p> <ul style="list-style-type: none"> • Small number of patients • Very narrow 1-month period of observation
Balduzzi et al [28]	Bergamo area and Emilia Romagna in Lombardia region of Italy	<ul style="list-style-type: none"> • Five pediatric patients with cancer identified in Lombardia with + test for SARS-CoV-2. • Diagnoses: ALL on maintenance (1), osteosarcoma after RT (1), hepatoblastomas (2), rhabdoid tumor (1) • None with severe course • No deaths • 17 pediatric patients • Diagnoses: ALL (4), AML (3), pilocytic astrocytoma (2), ependymoma (1), optic pathway glioma (1), and medulloblastoma (1), Burkitt lymphoma (1), Hodgkin lymphoma (1), non-Hodgkin lymphoma (1), rhabdomyosarcoma (1) osteosarcoma (1) • All patients: 14/17 (82%) with COVID-19 symptoms, all mild • Fever, 10/14 (71%) • Upper airway symptoms, 6/14 (43%) • Cough, 4/14 (29%) • Inpatient cohort, 8/8 (100%) with mild symptoms • Fever, 5/8 (63%) • Upper airway symptoms, 4/8 (50%) • Cough, 3/8 (38%) • Outpatient cohort, 6/9 (67%) with mild symptoms • Fever, 5/6 (83%) • Upper airway symptoms, 2/6 (33%) • Cough, 1/6 (17%) • Laboratory tests unremarkable • IgG and IgM antibodies + in 1/9 (11%) • RT-PCR screening for SARS-CoV-2 • 5 did not undergo RT-PCR screening • 4/12 + on RT-PCR screening • 14/17 had good quality baseline radiographs. • 14/14 had CT imaging findings consistent with COVID-19 infection • 15/17 (88%) had been receiving active cancer therapy • 9/15 (60%) receiving treatment for relapsed neoplasms 	<p>Limitations:</p> <ul style="list-style-type: none"> • Few cases; limited numbers • Data from period when testing not as robust
Mehrvar et al [this study]	<ul style="list-style-type: none"> • MAHAK Pediatric Cancer Treatment and Research Center (MPCTRC) in Tehran, Iran • All patients with cough, fever, and/or respiratory symptoms (with or without digestive symptoms) were screened for SARS-CoV-2 infection. • Period of study: March 18, 2020, to January 28, 2021 • During the period of the study 637 pediatric patients were admitted to or visited MPCTRC for cancer diagnoses and treatment; 356 had newly diagnosed neoplasms • 17/637 (2.7%) pediatric patients met diagnostic criteria for COVID-19 • Clinical presentations described by Carlotti <i>et al.</i>[15], and Dong <i>et al.</i>[16] used to divide the clinical symptoms into five categories [asymptomatic, mild, moderate, severe, clinical] 	<ul style="list-style-type: none"> • 17 pediatric patients • Diagnoses: ALL (4), AML (3), pilocytic astrocytoma (2), ependymoma (1), optic pathway glioma (1), and medulloblastoma (1), Burkitt lymphoma (1), Hodgkin lymphoma (1), non-Hodgkin lymphoma (1), rhabdomyosarcoma (1) osteosarcoma (1) • All patients: 14/17 (82%) with COVID-19 symptoms, all mild • Fever, 10/14 (71%) • Upper airway symptoms, 6/14 (43%) • Cough, 4/14 (29%) • Inpatient cohort, 8/8 (100%) with mild symptoms • Fever, 5/8 (63%) • Upper airway symptoms, 4/8 (50%) • Cough, 3/8 (38%) • Outpatient cohort, 6/9 (67%) with mild symptoms • Fever, 5/6 (83%) • Upper airway symptoms, 2/6 (33%) • Cough, 1/6 (17%) • Laboratory tests unremarkable • IgG and IgM antibodies + in 1/9 (11%) • RT-PCR screening for SARS-CoV-2 • 5 did not undergo RT-PCR screening • 4/12 + on RT-PCR screening • 14/17 had good quality baseline radiographs. • 14/14 had CT imaging findings consistent with COVID-19 infection • 15/17 (88%) had been receiving active cancer therapy • 9/15 (60%) receiving treatment for relapsed neoplasms 	<p>Author conclusions</p> <ul style="list-style-type: none"> • A majority of pediatric patients with cancer who experience mild COVID-19 symptoms can most likely receive supportive care at home without hospitalization • However, COVID-19 can be fatal in a meaningful fraction of infected pediatric patients, and when identified should be admitted and receive best care available at the time <p>Limitations:</p> <ul style="list-style-type: none"> • While diagnoses supported by strict clinical guidelines and computed tomography imaging for diverse reasons state of the art RT-PCR testing was not available for all

ALL = acute lymphoblastic leukemia; AML = acute myeloid leukemia; CI = confidence interval; RT = radiation therapy; RT-PCR = reverse transcriptase polymerase chain reaction.

trast. Representative CT images from cases 2 and 3 (inpatient cohort) and case 10 (outpatient cohort) are shown in Fig. 2.>

Molecular detection and treatment of COVID-19

SARS-CoV-2-specific IgG and IgM antibody levels were evaluated in nine patients, and were negative in all patients except for case 13 (IgG: 6.78; IgM: 3.78). Twelve patients had RT-PCR screening for SARS-CoV-2 performed, and four were positive (cases 12, 16, 17, and 18). Five patients did not undergo RT-PCR screening for SARS-CoV-2 infection.

Before the COVID-19 pandemic, all patients were receiving active cancer therapy, with the exception of cases 16 and 18 who were receiving follow-up examinations. Nine patients were receiving treatment for relapsed neoplasms. Case 7 was receiving treatment for a second ALL relapse, and case 4 was receiving chemotherapy for relapsed AML after having undergone a bone marrow transplant. The remaining thirteen patients were receiving various phases of chemotherapy treatment at the time of COVID-19 diagnosis (Table 5).

At the time of this writing, three patients in our study had died of COVID-19, and all other patients had recovered. The deceased patients were a 16-year-old male with Burkitt lymphoma who was

receiving chemotherapy for recurrence, a 13-year-old male with osteosarcoma who was receiving chemotherapy after surgery, and a 10-year-old male with ALL who was in a subsequent maintenance phase of chemotherapy after relapse. All three patients died because of respiratory failure, despite hospitalization and treatment with hydroxychloroquine, oseltamivir, and azithromycin.

Discussion

Despite the devastation of the COVID-19 pandemic, we still know very little about its biology in children with cancer. Some studies have reported that patients with cancer have an increased risk of contracting COVID-19 [21–23]. Our study is the first report of COVID-19 in children with cancer referred to a cancer center in Iran. During the period of our study, 17 of 637 patients contracted COVID-19, according to our institutional criteria. Unfortunately, three of these patients who were hospitalized and received oseltamivir, hydroxychloroquine, and azithromycin therapy died of COVID-19. Because nine children in our study refused hospitalization but recovered at home with only supportive care, we cannot draw meaningful conclusions as to the benefit of hospitalization coupled with antiviral/hydroxychloroquine therapy on the outcomes of our patients.

In April 2020, Ruggiero *et al.* systematically reviewed published reports of pediatric patients with cancer who contracted COVID-19 [24]. At that time, information on only one pediatric oncology patient with COVID-19 had been published [25]. Chen *et al.* reported the experience of an 8-year-old male patient with ALL in Wuhan, China, who contracted COVID-19 6 days after completing his maintenance chemotherapy regimen. The authors suggested that SARS-CoV-2 was transmitted to the patient from his attending physician at the hospital [25].

To date the literature describing COVID-19 in pediatric patients with a diagnosis of cancer remains very sparse (Table 6). Hrusak *et al.* conducted a web-based survey characterizing COVID-19 cases in pediatric hematology-oncology centers. Thirty-two countries participated in the survey, and of 200 cases who received SARS-CoV-2 testing, only eight were positive. Moreover, the severity of COVID-19 symptoms was mild in these cases [26]. The Memorial Sloan Kettering Cancer Center established a program for screening COVID-19 in pediatric oncology patients (Table 6). Over a brief one-month period from March 10 to April 12, 2020, 20 of 178 patients who were screened for SARS-CoV-2 infections were positive. The mean age of these patients was 15.9 years, and only three were female. One of the patients was hospitalized for a noncritical condition, three asymptomatic patients were hospitalized because of their cancer comorbidity, and the remaining 16 experienced mild COVID-19 symptoms and recovered at home [27]. Finally through March 18, 2020, only five pediatric oncology cases exhibiting mild COVID-19 symptoms were reported in the Lombardy region of Italy. These cases included patients with ALL in second remission, osteosarcoma, hepatoblastoma, and rhabdoid tumors. Three patients recovered at home, and two were hospitalized without any antiviral medications [28].

Our findings and those of others suggest that treatment in the outpatient setting without antivirals or antibiotics is a viable option for pediatric oncology patients with COVID-19. Indeed, all of the patients in our study with mild COVID-19 symptoms who refused hospitalization recovered at home. However, our experience also demonstrates that COVID-19 can be fatal in a meaningful fraction of infected pediatric patients, and it is hoped that going forward when these cases are recognized, the availability of novel therapeutics and our greater understanding of the management of this disease may help in their management.

Conclusion

We suggest that a majority of pediatric patients with cancer who experience mild COVID-19 symptoms can most likely receive supportive care at home without hospitalization helping to prevent further SARS-CoV-2 transmission. Finally, the quality of molecular diagnostic testing for SARS-CoV-2 infections in Iran should be improved.

Conflict of interest

The authors declare that there is not any conflict of interest.

Acknowledgment

The authors thank Nisha Badders for editing the manuscript.

References

- Lee PI, Hu YL, Chen PY, Huang YC, Hsueh PR. Are children less susceptible to COVID-19? *J Microbiol Immunol Infect* 2020;53(3):371–2.
- Bai Y, Yao L, Wei T, et al. Presumed asymptomatic carrier transmission of COVID-19. *JAMA* 2020;323(14):1406–7.
- Qiu H, Wu J, Hong L, Luo Y, Song Q, Chen D. Clinical and epidemiological features of 36 children with coronavirus disease 2019 (COVID-19) in Zhejiang, China: an observational cohort study. *Lancet Infect Dis* 2020;20(6):689–96.
- Wang D, Hu B, Hu C, et al. Clinical characteristics of 138 hospitalized patients with 2019 novel coronavirus-infected pneumonia in Wuhan, China. *JAMA* 2020;323(11):1061–9.
- Li Q, Guan X, Wu P, et al. Early transmission dynamics in Wuhan, China, of novel coronavirus-infected pneumonia. *N Engl J Med* 2020;382(13):1199–1207.
- Huang C, Wang Y, Li X, et al. Clinical features of patients infected with 2019 novel coronavirus in Wuhan, China. *Lancet*. 2020;395(10223):497–506.
- She J, Liu L, Liu W. COVID-19 epidemic: disease characteristics in children. *J Med Virol* 2020;92(7):747–54.
- Lee PI, Hsueh PR. Emerging threats from zoonotic coronaviruses from SARS and MERS to 2019-nCoV. *J Microbiol Immunol Infect* 2020;53(3):365–7.
- Xia W, Shao J, Guo Y, Peng X, Li Z, Hu D. Clinical and CT features in pediatric patients with COVID-19 infection: Different points from adults. *Pediatr Pulmonol* 2020;55(5):1169–74.
- Mahmoudi S, Mehdizadeh M, Badv RS, et al. The coronavirus disease 2019 (COVID-19) in children: a study in an Iranian Children's Referral Hospital. *Infect Drug Resist* 2020;13:2649–55.
- Hanna TP, Evans GA, Booth CM. Cancer, COVID-19 and the precautionary principle: prioritizing treatment during a global pandemic. *Nat Rev Clin Oncol* 2020;17(5):268–70.
- Zhou F, Yu T, Du R, et al. Clinical course and risk factors for mortality of adult inpatients with COVID-19 in Wuhan, China: a retrospective cohort study. *Lancet* 2020;395(10229):1054–62.
- Liang W, Guan W, Chen R, et al. Cancer patients in SARS-CoV-2 infection: a nationwide analysis in China. *Lancet Oncol* 2020;21(3):335–7.
- Burki TK. Cancer guidelines during the COVID-19 pandemic. *Lancet Oncol* 2020;21(5):629–30.
- Carlotti ACP, Carvalho WB, Johnston C, Rodriguez IS, Delgado AF. COVID-19 diagnostic and management protocol for pediatric patients. *Clinics* 2020;75:e1894.
- Dong Y, Mo X, Hu Y, et al. Epidemiology of COVID-19 among children in China. *Pediatrics* 2020;145(6):e20200702.
- Chen ZM, Fu JF, Shu Q, et al. Diagnosis and treatment recommendations for pediatric respiratory infection caused by the 2019 novel coronavirus. *World J Pediatr* 2020;16(3):240–6.
- Brown JR, Atkinson L, Shah D, Harris K. Validation of an extraction-free RT-PCR protocol for detection of SARS-CoV2 RNA. *MedRxiv* 2020.
- Resolução SS-28, 17-03-2020. *Diário Oficial do Estado de São Paulo*.130(54):24–25.
- Karimi A, Tabatabaei SR, Rajabnejad M, et al. An algorithmic approach to diagnosis and treatment of coronavirus disease 2019 (COVID-19) in children: Iranian expert's consensus statement. *Arch Pediatr Infect Dis* 2020;8(2):e102400.
- Yu J, Ouyang W, Chua ML, Xie C. SARS-CoV-2 transmission in patients with cancer at a tertiary care hospital in Wuhan, China. *JAMA Oncol* 2020;6(7):1108–10.
- Dai MY, Liu D, Liu M, et al. Abstract CT406: Patients with cancer appear more vulnerable to SARS-COV-2: A multi-center study during the COVID-19 outbreak. *AACR* 2020.
- Robilotti EV, Babady NE, Mead PA, et al. Determinants of COVID-19 disease severity in patients with cancer. *Nat Med* 2020;26(8):1218–23.
- Ruggiero A, Romano A, Attinà G. Covid-19 and children with cancer: are they at increased risk of infection? *Pediatr Res* 2020. doi:10.1038/s41390-020-0919-1.

- [25] Chen Z, Xiong H, Li J, et al. COVID-19 with post-chemotherapy agranulocytosis in childhood acute leukemia: a case report. *Zhonghua Xue Ye Xue Za Xhi* 2020;41(4):341–3.
- [26] Hrusak O, Kalina T, Wolf J, et al. Flash survey on severe acute respiratory syndrome coronavirus-2 infections in pediatric patients on anti-cancer treatment. *Eur J Cancer* 2020;132:11–16.
- [27] Boulad F, Kamboj M, Bouvier N, Mauguen A, Kung AL. COVID-19 in children with cancer in New York City. *JAMA Oncol* 2020;6(9):1459–60.
- [28] Balduzzi A, Brivio E, Rovelli A, et al. Lessons after the early management of the COVID-19 outbreak in a pediatric transplant and hemato-oncology center embedded within a COVID-19 dedicated hospital in Lombardia, Italy. *Estote parati. Bone Marrow Transplant* 2020;55(1):1900–5.